

Correction of Deep Bite in Adults Using the Invisalign System

ALDO GIANCOTTI, DDS
GIANLUCA MAMPIERI, DDS
MARIO GRECO, DDS

Deep overbite is commonly treated by molar extrusion, incisor intrusion, or both. Careful diagnostic assessment is needed to determine the best treatment approach. Patients with structural deep bites may require orthognathic surgery for full correction.¹

The amount of incisor exposure in smiling is an important consideration in deep-bite cases. When the maxillary incisor display is correct, maxillary incisor intrusion is unnecessary; treatment should involve intrusion and leveling of the mandibular anterior teeth to avoid flattening of the smile arc.² Any maxillary incisor intrusion or mandibular leveling should be carefully monitored during treatment to maintain proper incisor exposure while effectively correcting the deep bite.

After the development of thermoformed appliances that could be used for minor tooth movements,³⁻⁷ the Invisalign* system was introduced for treatment of moderate malocclusions.⁸⁻¹³ In 2004, Wheeler reported that Invisalign could be used in patients with anterior and posterior crossbites, deep bites, anterior open bites or shallow overbites, and periodontal problems.¹⁴ The present article describes the use of Invisalign appliances for the correction of deep bite in adult patients with normal skeletal patterns.

*Registered trademark of Align Technology, Inc., 881 Martin Ave., Santa Clara, CA 95050; www.aligntech.com.

Case 1

A 23-year-old female presented with a Class I malocclusion, a deep bite, and mild crowding in both arches (Fig. 1). Treatment involved 23 upper and 29 lower aligners. After 15 months of initial treatment, another six months of Case Refinement was needed to finish the lower alignment (Figs. 2,3).

The upper and lower crowding was corrected with interproximal reduction. The deep bite was opened by leveling the mandibular arch, using controlled proclination of the mandibular incisors and only slight intrusion of the maxillary incisors, thus maintaining the smile arc. The patient's good posterior occlusal relationship was preserved.

Case 2

A 33-year-old male presented with a Class I malocclusion, a deep bite, and severe crowding in both arches (Fig. 4). Treatment involved 22 upper and 32 lower aligners. Initial treatment lasted 16 months, but Case Refinement was needed for an additional five months to improve the alignment in both arches (Figs. 5,6).

The patient's crowding was corrected with upper and lower incisor proclination and minor interproximal reduction in the lower left quadrant. The deep bite was opened with slight maxillary

Drs. Giancotti and Mampieri are Assistant Professors and Dr. Greco is a postgraduate student, Department of Orthodontics, University of Rome "Tor Vergata", Rome, Italy. Contact Dr. Giancotti at Viale Gorizia 24/c, 00198 Rome, Italy; e-mail: giancott@uniroma2.it.



Dr. Giancotti



Dr. Mampieri



Dr. Greco

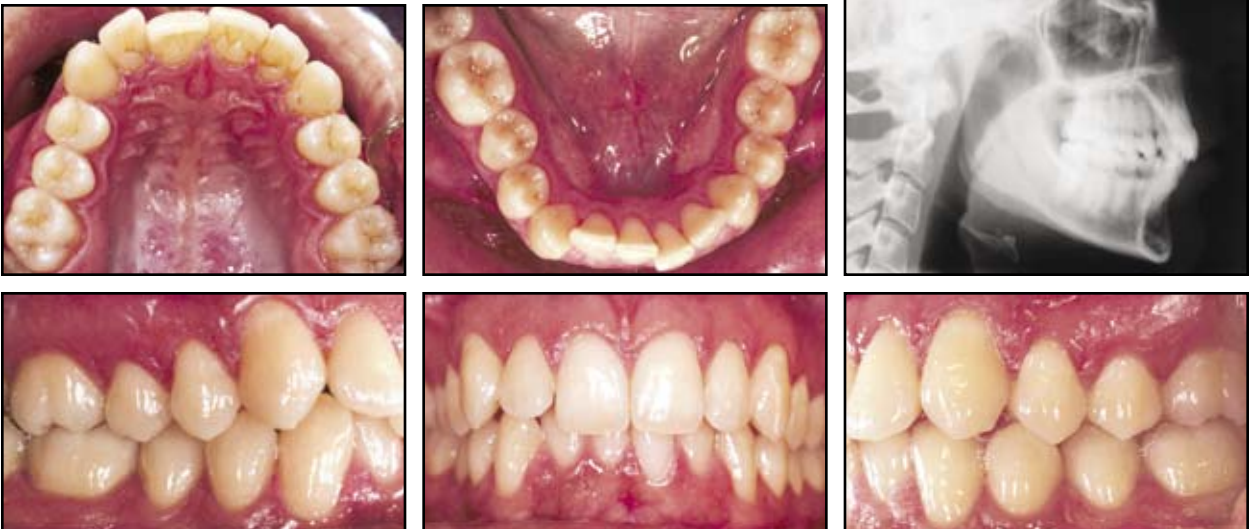
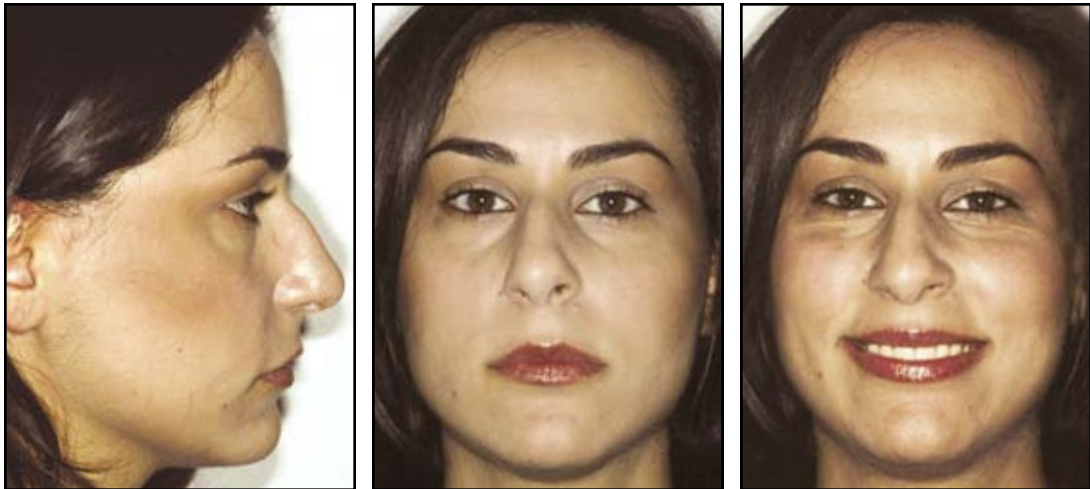
Fig. 1 Case 1. 23-year-old female patient with Class I malocclusion, deep bite, and mild crowding in both arches before treatment.

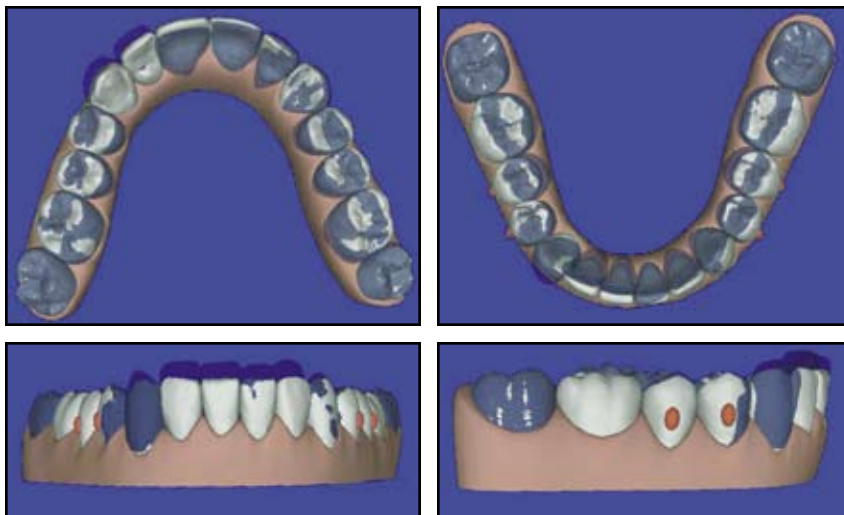


Fig. 2 Case 1. ClinCheck* superimpositions.

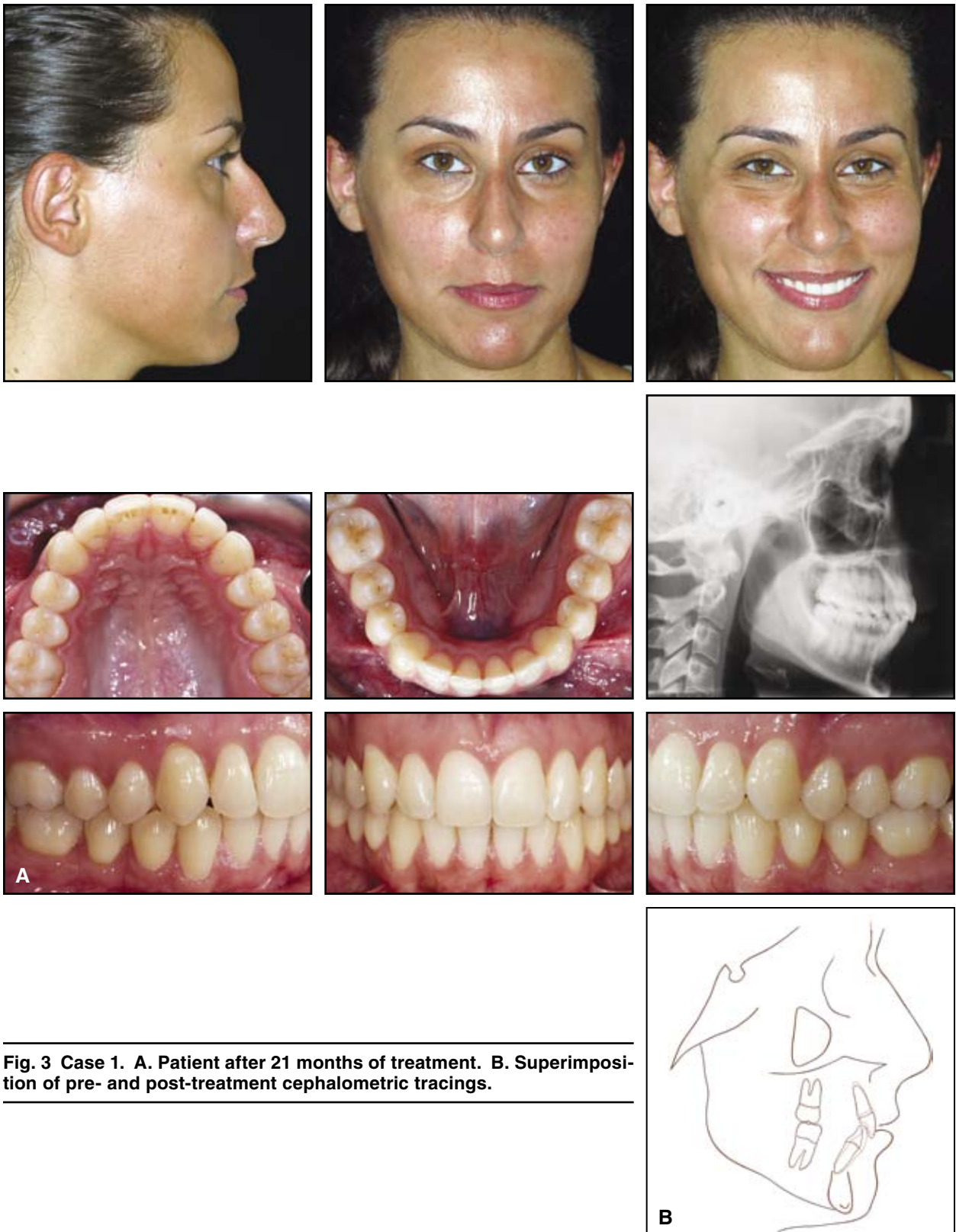


Fig. 3 Case 1. A. Patient after 21 months of treatment. B. Superimposition of pre- and post-treatment cephalometric tracings.

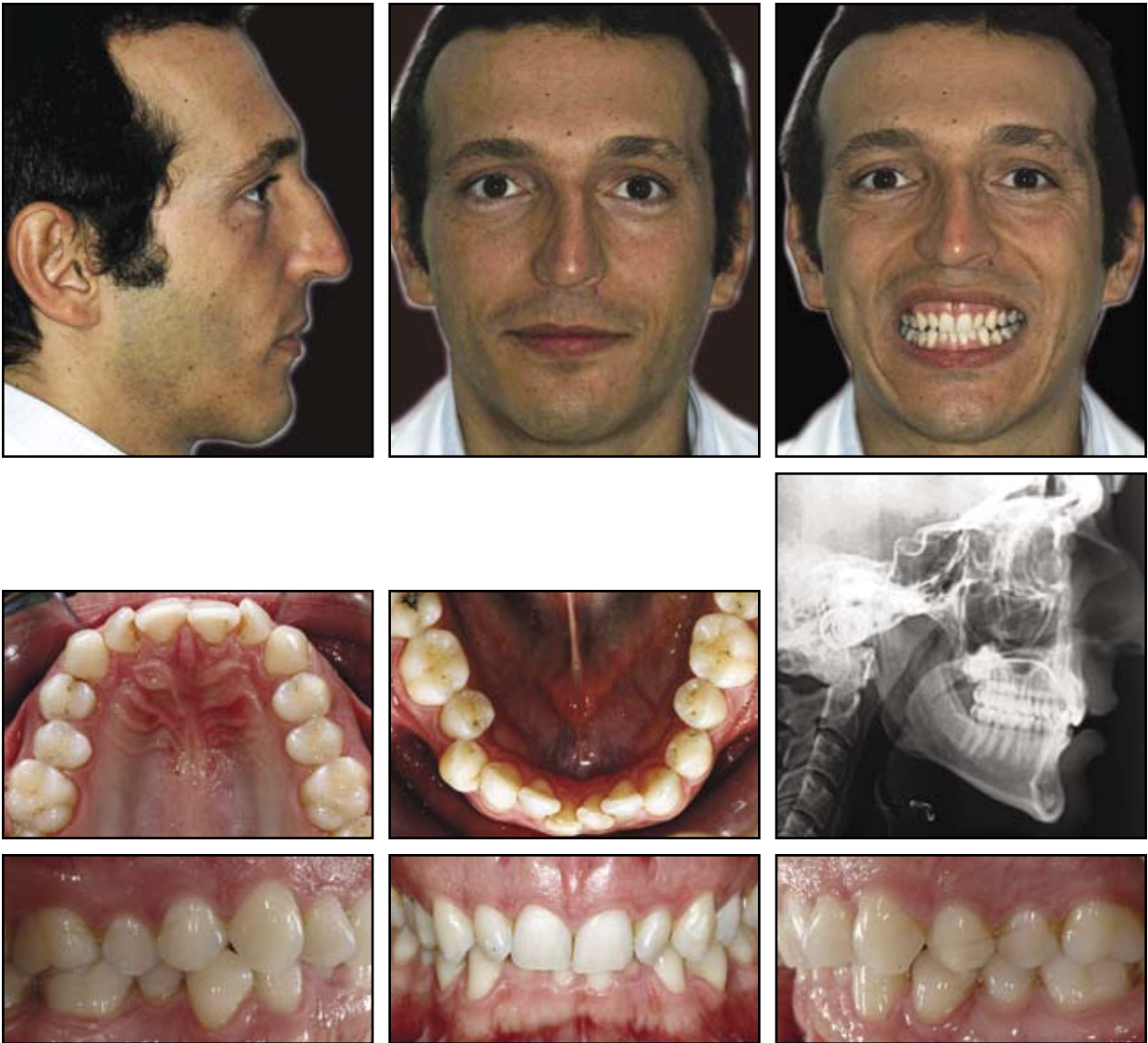

Fig. 4 Case 2. 33-year-old male patient with Class I malocclusion, deep bite, and severe crowding in both arches before treatment.

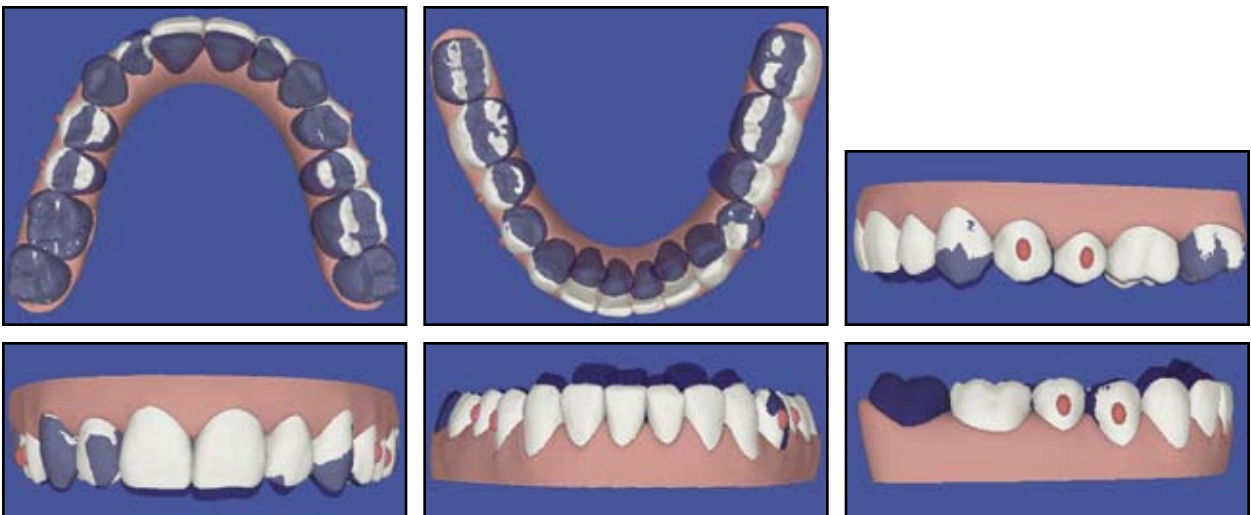

Fig. 5 Case 2. ClinCheck superimpositions.

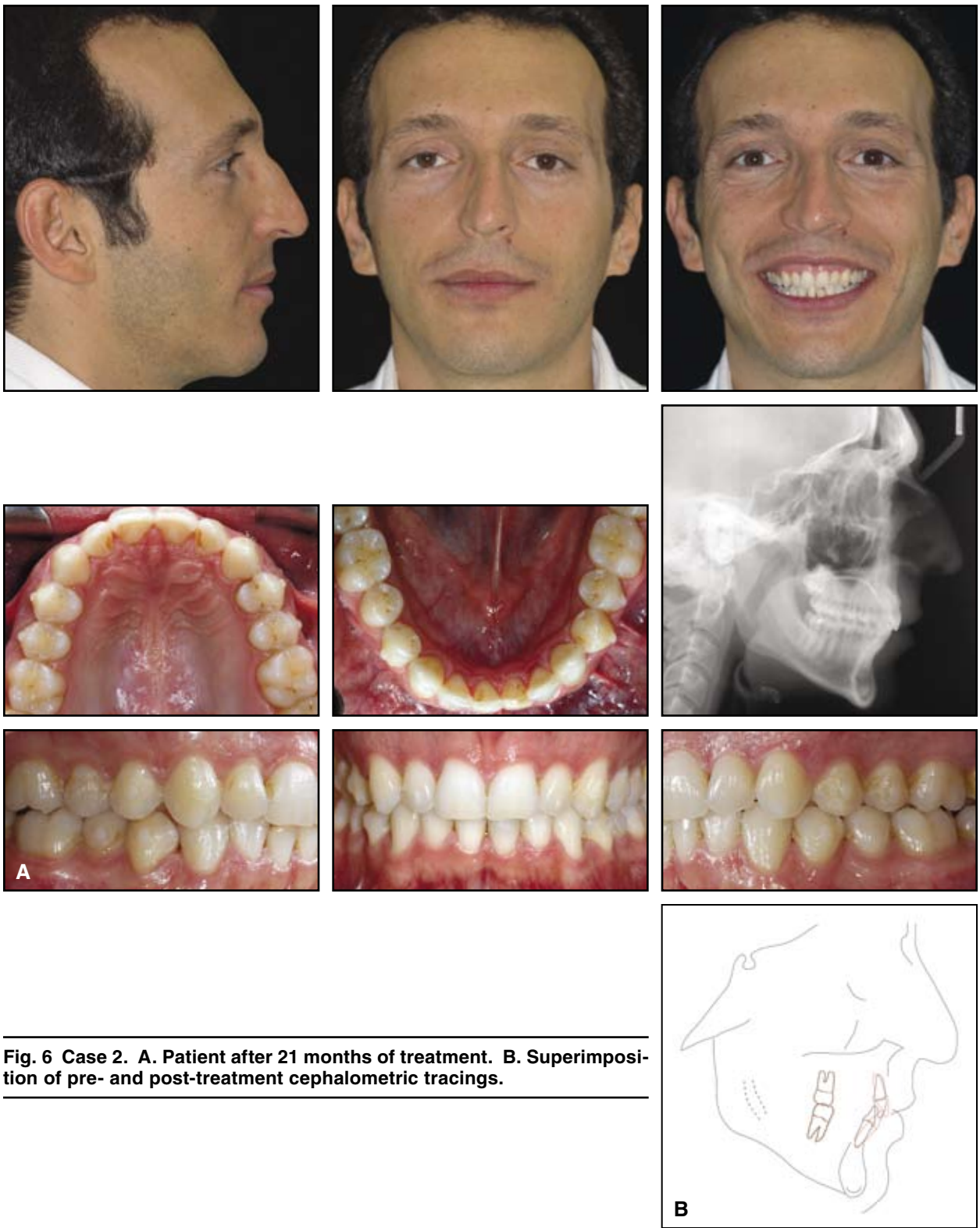


Fig. 6 Case 2. A. Patient after 21 months of treatment. B. Superimposition of pre- and post-treatment cephalometric tracings.

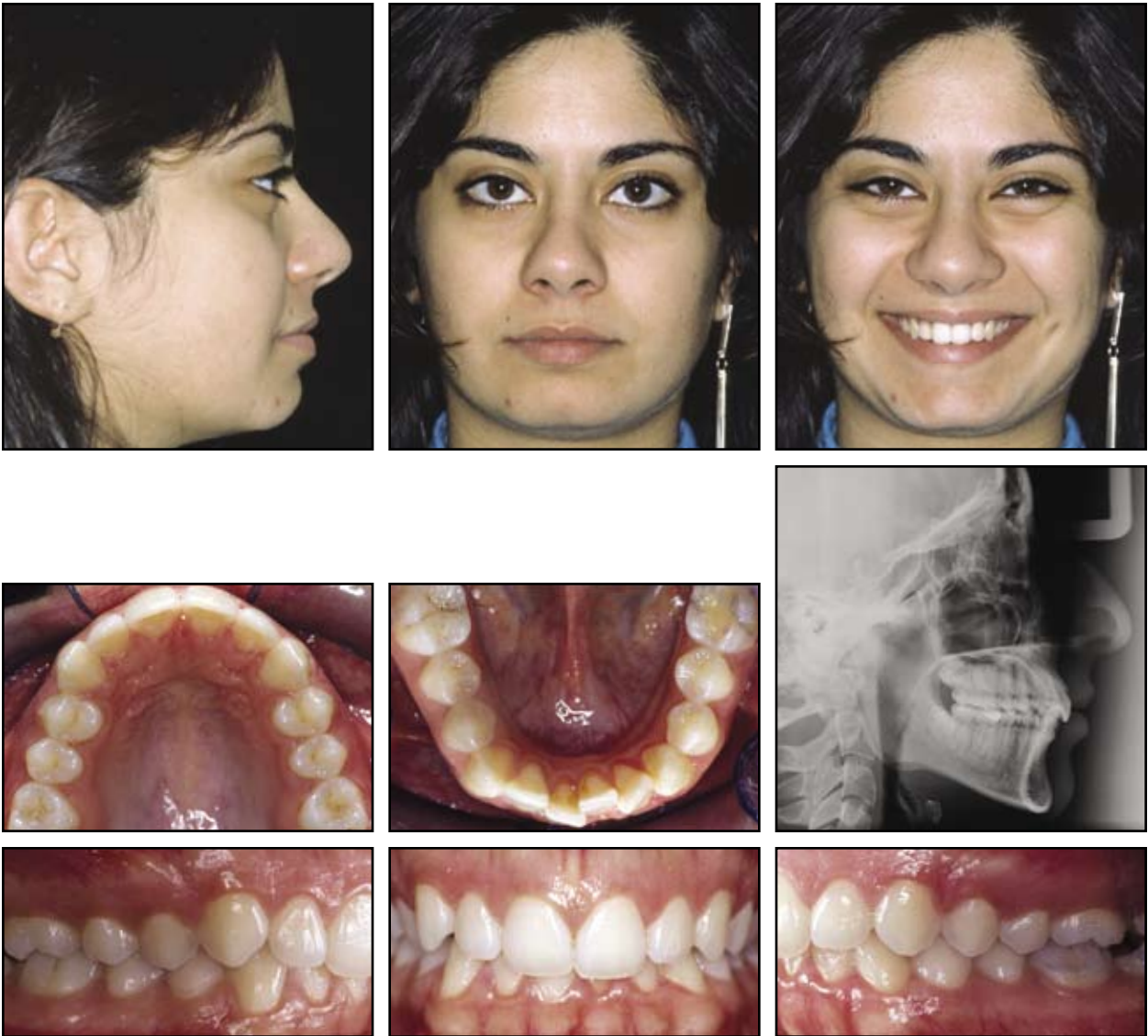


Fig. 7 Case 3. 23-year-old female patient with Class I malocclusion, deep bite, and moderate crowding in mandibular arch before treatment.

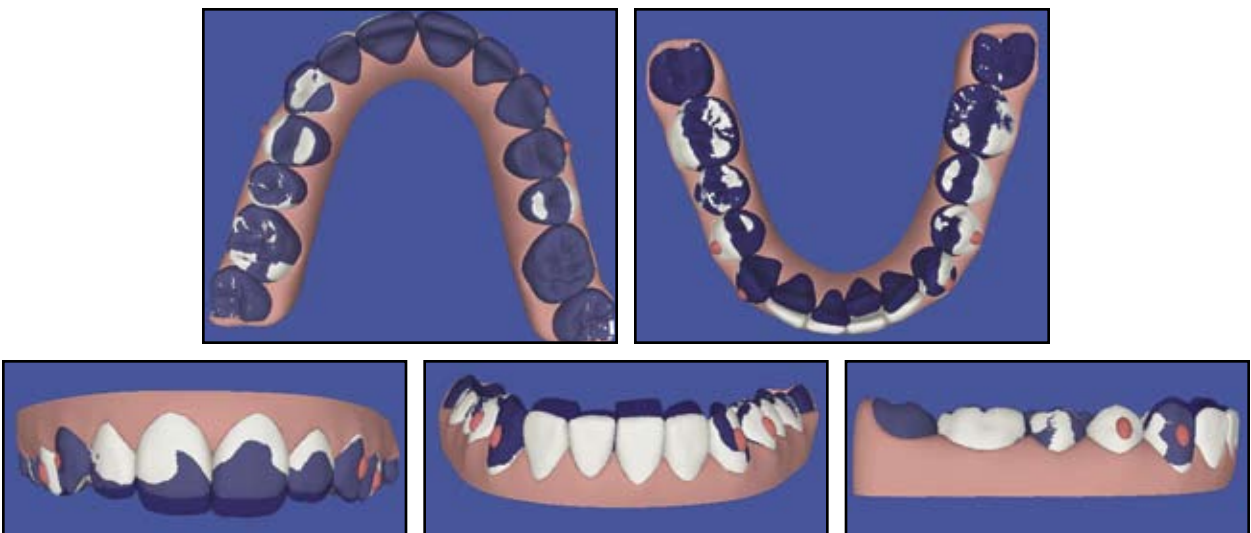


Fig. 8 Case 3. ClinCheck superimpositions.

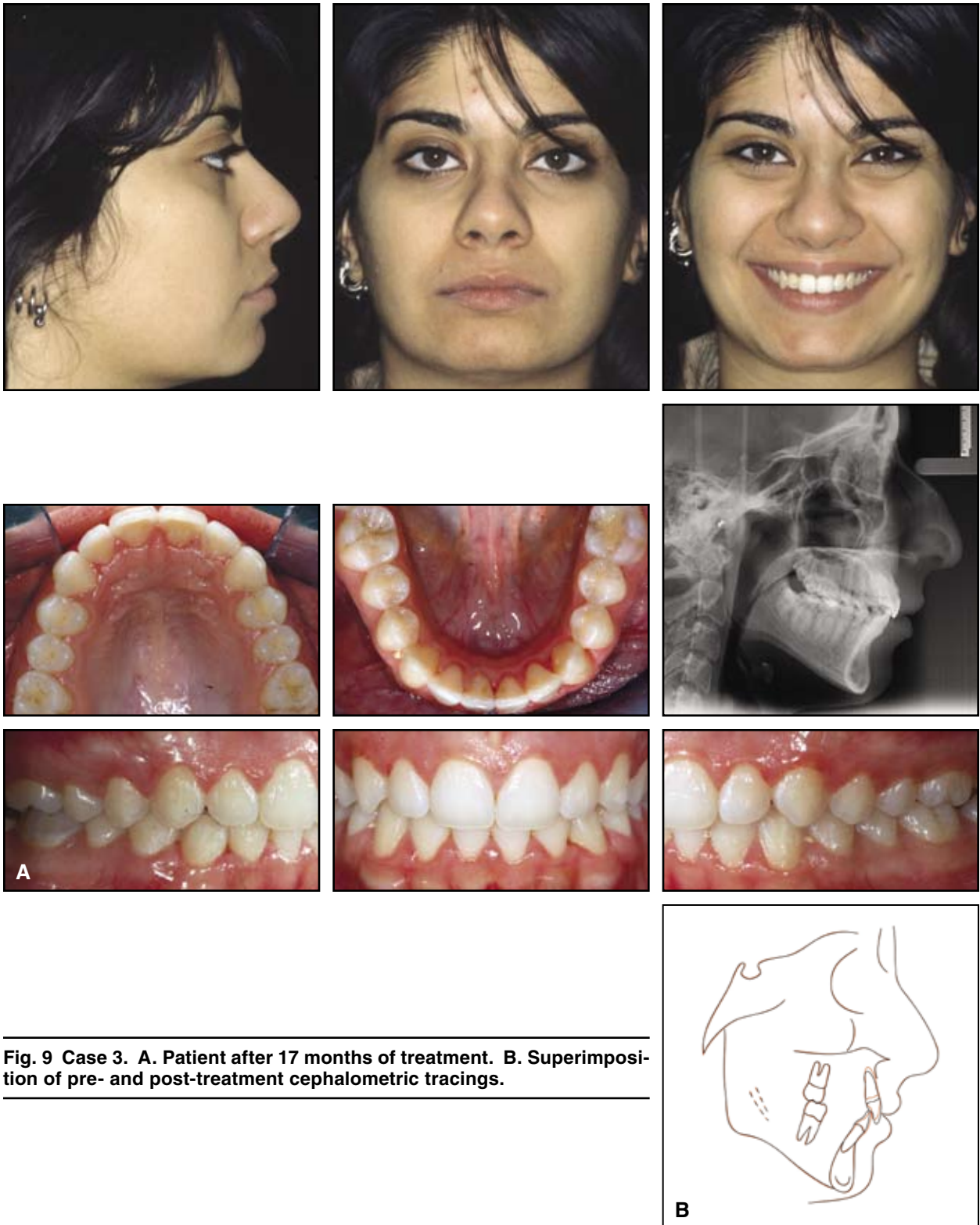


Fig. 9 Case 3. A. Patient after 17 months of treatment. B. Superimposition of pre- and post-treatment cephalometric tracings.

incisor intrusion and proclination, along with mandibular arch leveling; controlled mandibular incisor proclination improved the facial esthetics and reduced the patient's gummy smile. The posterior occlusal relationship was maintained.

Case 3

A 23-year-old female presented with a Class I malocclusion, a deep bite, and moderate crowding in the mandibular arch (Fig. 7). Eleven upper and 33 lower aligners were used over 17 months of treatment (Figs. 8,9).

The deep bite was corrected through slight intrusion of the maxillary incisors and mandibular arch leveling, while controlled proclination of the mandibular incisors reduced crowding. An appropriate posterior occlusal relationship was maintained.

Discussion

Treatment of deep overbite in a patient with a normal skeletal pattern should aim to produce rapid disclusion of the mandibular incisors and to improve the incisor display without flattening the smile arc. The importance of leveling the curve of Spee in the correction of deep bite has been well documented.¹⁵⁻²⁰

Ng and colleagues found that while true incisor intrusion can be achieved with a variety of appliances, the use of segmented mechanics is especially effective.²¹ The amount of intrusion depends on the dental arch, with more intrusion possible in the mandible; individual patient considerations, including the distance between the roots and cortical bone; and the chosen mechanics.

According to Boyd, the Invisalign system can be effective in treating deep bite because of the predictability of the intrusion and leveling mechanics designed during the ClinCheck* procedure.²² In addition, the disclusion caused by the aligners avoids the potential occlusal interferences of fixed appliances. Moreover, the Invisalign system is generally well accepted by the patient, assuring good compliance with the treatment regimen.

*Registered trademark of Align Technology, Inc., 881 Martin Ave., Santa Clara, CA 95050; www.aligntech.com.

REFERENCES

1. Hering, H.K.; Ruf, S.; and Pancherz, H.: Orthodontic treatment of openbite and deepbite high-angle malocclusions, *Angle Orthod.* 69:470-477, 1999.
2. Sarver, D.M.: The importance of incisor positioning in the esthetic smile: The smile arc, *Am. J. Orthod.* 120:98-111, 2001.
3. Giancotti, A.; Romanini, G.; and Docimo, R.: Early treatment of anterior crossbite with an Essix-based appliance, *J. Clin. Orthod.* 38:161-164, 2004.
4. Kesling, H.D.: The philosophy of the Tooth Positioning Appliance, *Am. J. Orthod.* 31:297-304, 1945.
5. McNamara, J.A.; Kramer, K.L.; and Juenker, J.P.: Invisible retainers, *J. Clin. Orthod.* 19:570-578, 1985.
6. Ponitz, R.J.: Invisible retainers, *Am. J. Orthod.* 59:266-272, 1971.
7. Sheridan, J.J.; LeDoux, W.; and McMinn, R.: Essix retainers: Fabrication and supervision for permanent retention, *J. Clin. Orthod.* 27:37-45, 1993.
8. Boyd, R.L. and Vlaskalic, V.: Three-dimensional diagnosis and orthodontic treatment of complex malocclusions with the Invisalign Appliance, *Semin. Orthod.* 7:274-293, 2001.
9. Ellis, C.P.: Invisalign and changing relationships, *Am. J. Orthod.* 126:20A-21A, 2004.
10. Miller, R.J. and Derakhshan, M.: The Invisalign System: Case report of a patient with deep bite, upper incisor flaring, and severe curve of Spee, *Semin. Orthod.* 8:43-50, 2002.
11. Miller, R.J.; Duong, T.T.; and Derakhshan, M.: Lower incisor extraction treatment with the Invisalign system, *J. Clin. Orthod.* 36:95-102, 2002.
12. Sheridan, J.J.: The Readers' Corner, *J. Clin. Orthod.* 38:544-545, 2004.
13. Vlaskalic, V. and Boyd, R.: Orthodontic treatment of a mildly crowded malocclusion using the Invisalign System, *Austral. Orthod. J.* 17:41-46, 2001.
14. Wheeler, T.T.: Invisalign material studies, *Am. J. Orthod.* 125:19A, 2004.
15. Baldrige, D.W.: Leveling the curve of Spee: Its effect on mandibular arch length, *J. Pract. Orthod.* 3:26-41, 1969.
16. Braun, S.; Hnat, W.P.; and Johnson, B.E.: The curve of Spee revisited, *Am. J. Orthod.* 110:206-210, 1996.
17. De Praeter, J.; Dermaut, L.; Martens, G.; and Kuijpers-Jagtman, A.M.: Long-term stability of the leveling of the curve of Spee, *Am. J. Orthod.* 121:266-272, 2002.
18. Germane, N.; Staggers, J.A.; Rubenstein, L.; and Revere, J.T.: Arch length considerations due to the curve of Spee: A mathematical model, *Am. J. Orthod.* 102:251-255, 1992.
19. Koyama, T.: A comparative analysis of the curve of Spee (lateral aspect) before and after orthodontic treatment—with particular reference to overbite patients, *J. Nihon Univ. Sch. Dent.* 21:25-34, 1979.
20. Spee, F.: The gliding path of the mandible along the skull, *J. Am. Dent. Assoc.* 100:670-675, 1980.
21. Ng, J.; Major, P.W.; Heo, G.; and Flores-Mir, C.: True incisor intrusion attained during orthodontic treatment: A systematic review and meta-analysis, *Am. J. Orthod.* 128:212-219, 2005.
22. Boyd, R.L.: Complex orthodontic treatment using a new protocol for the Invisalign appliance, *J. Clin. Orthod.* 41:525-547, 2007.